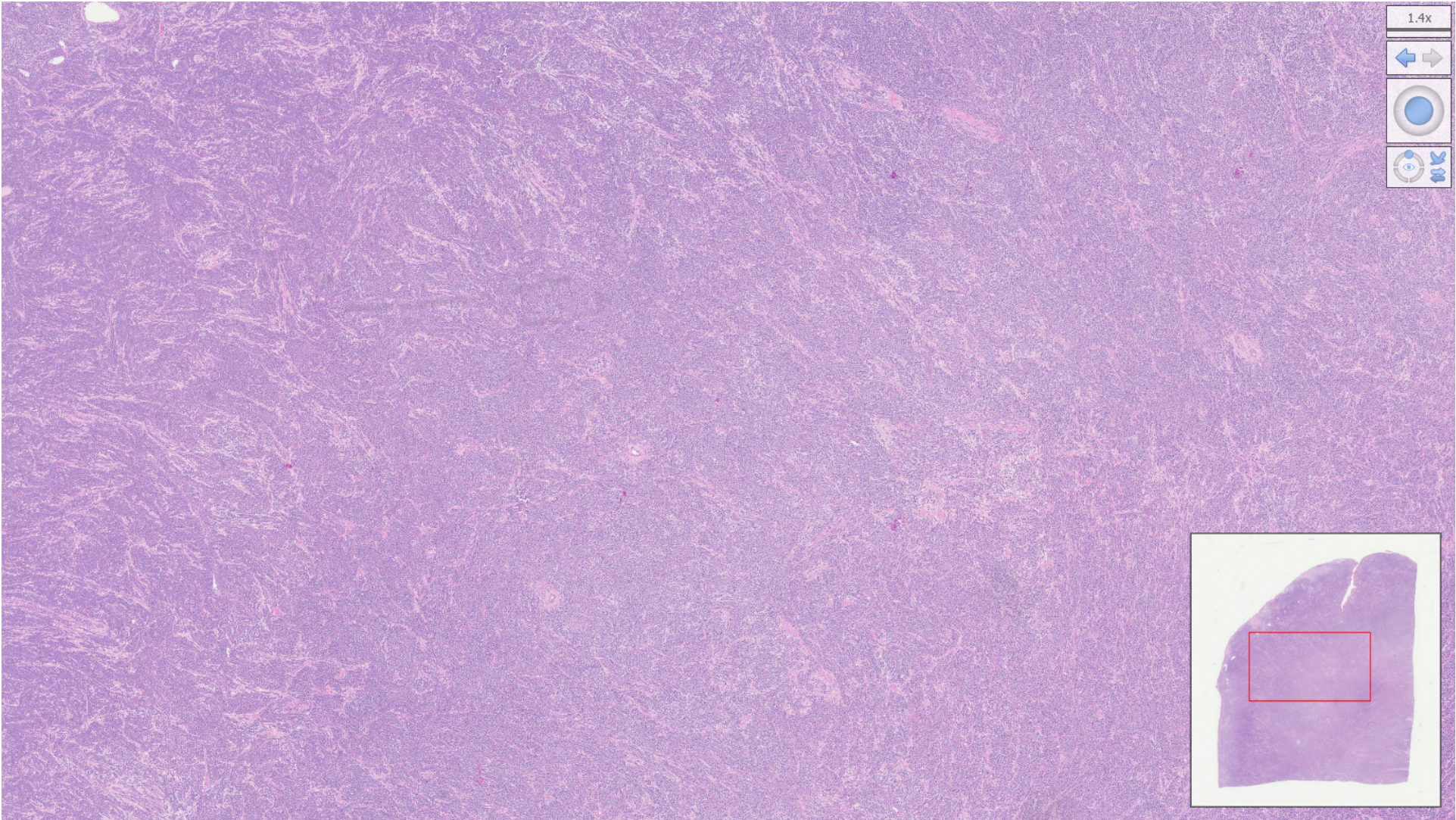
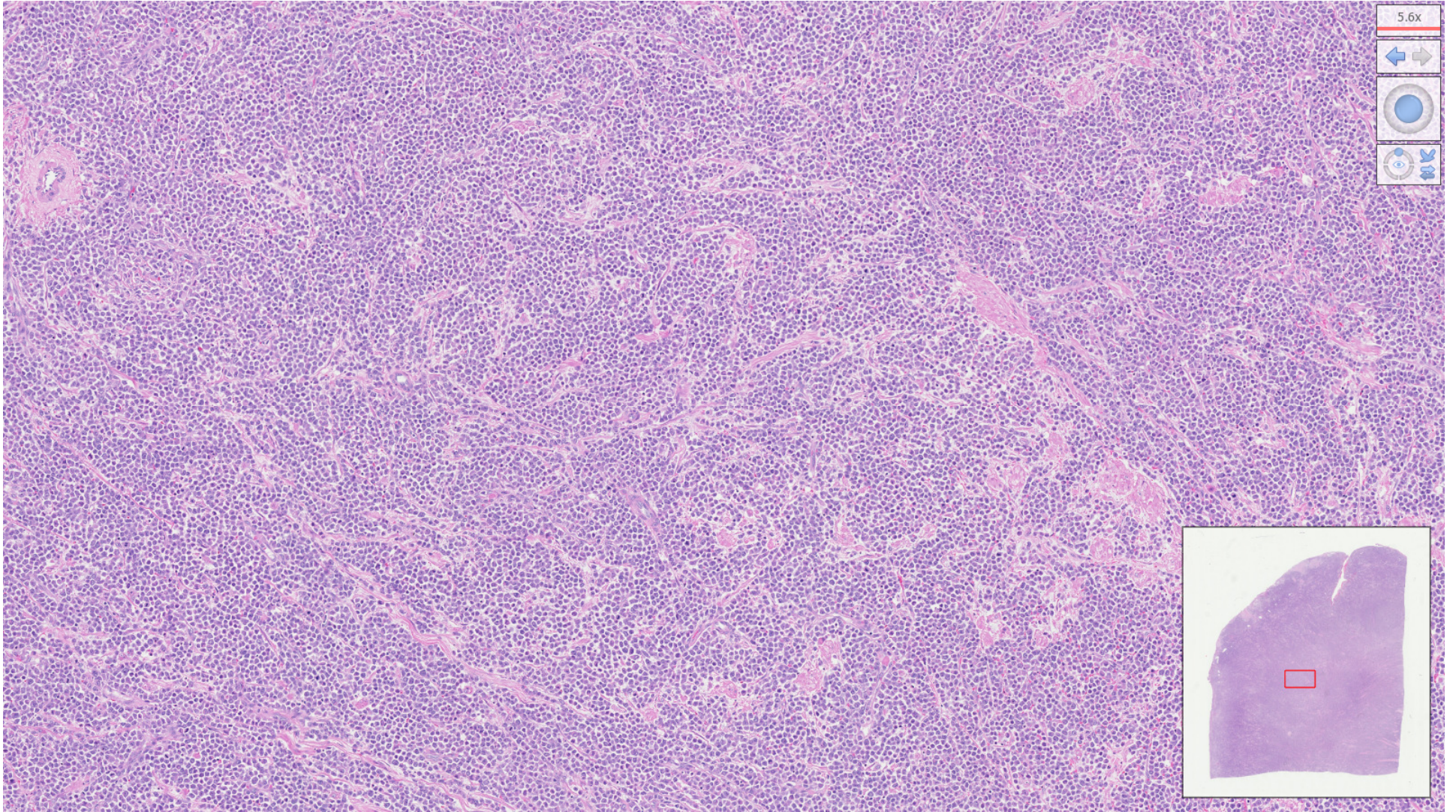
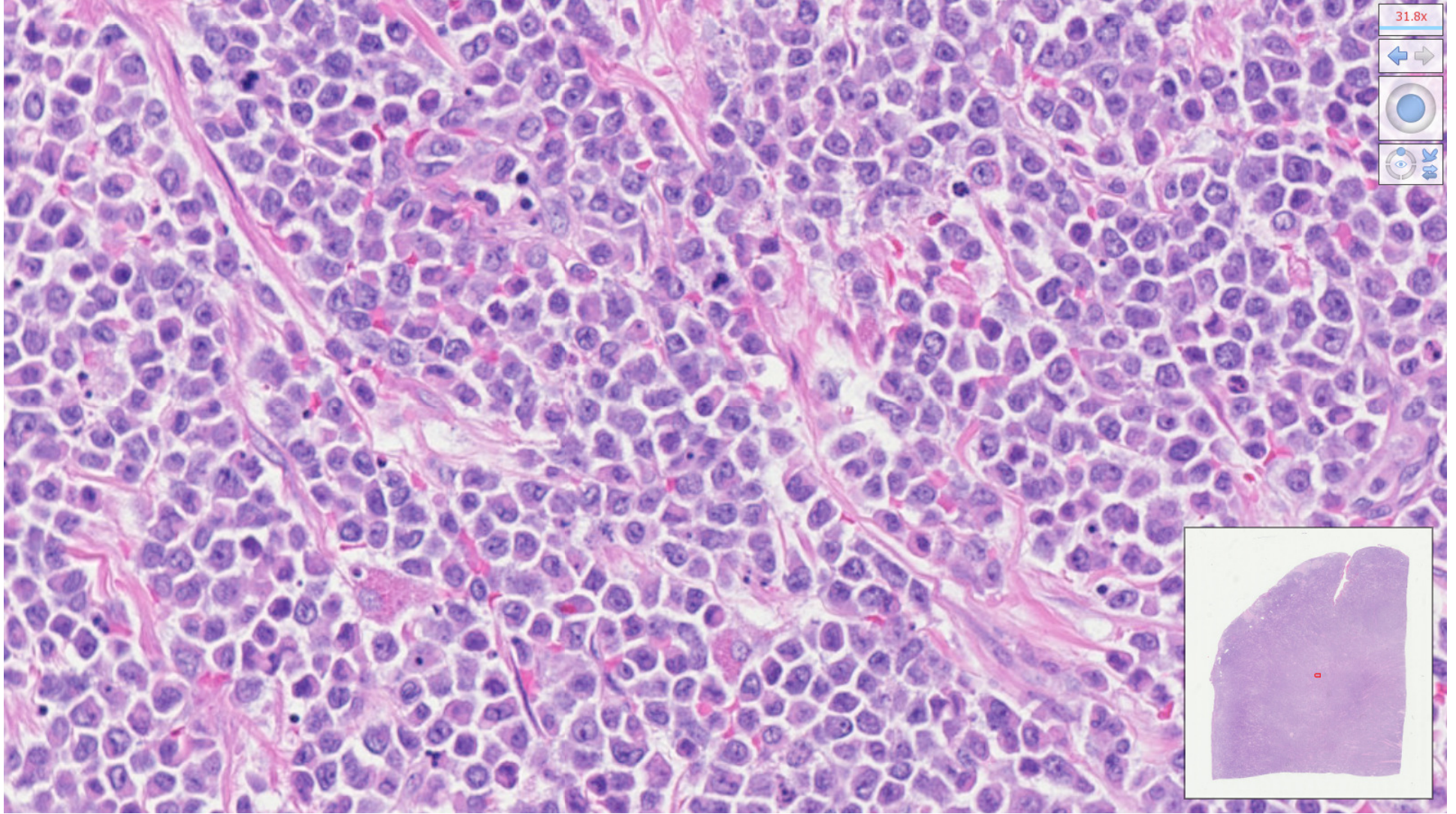


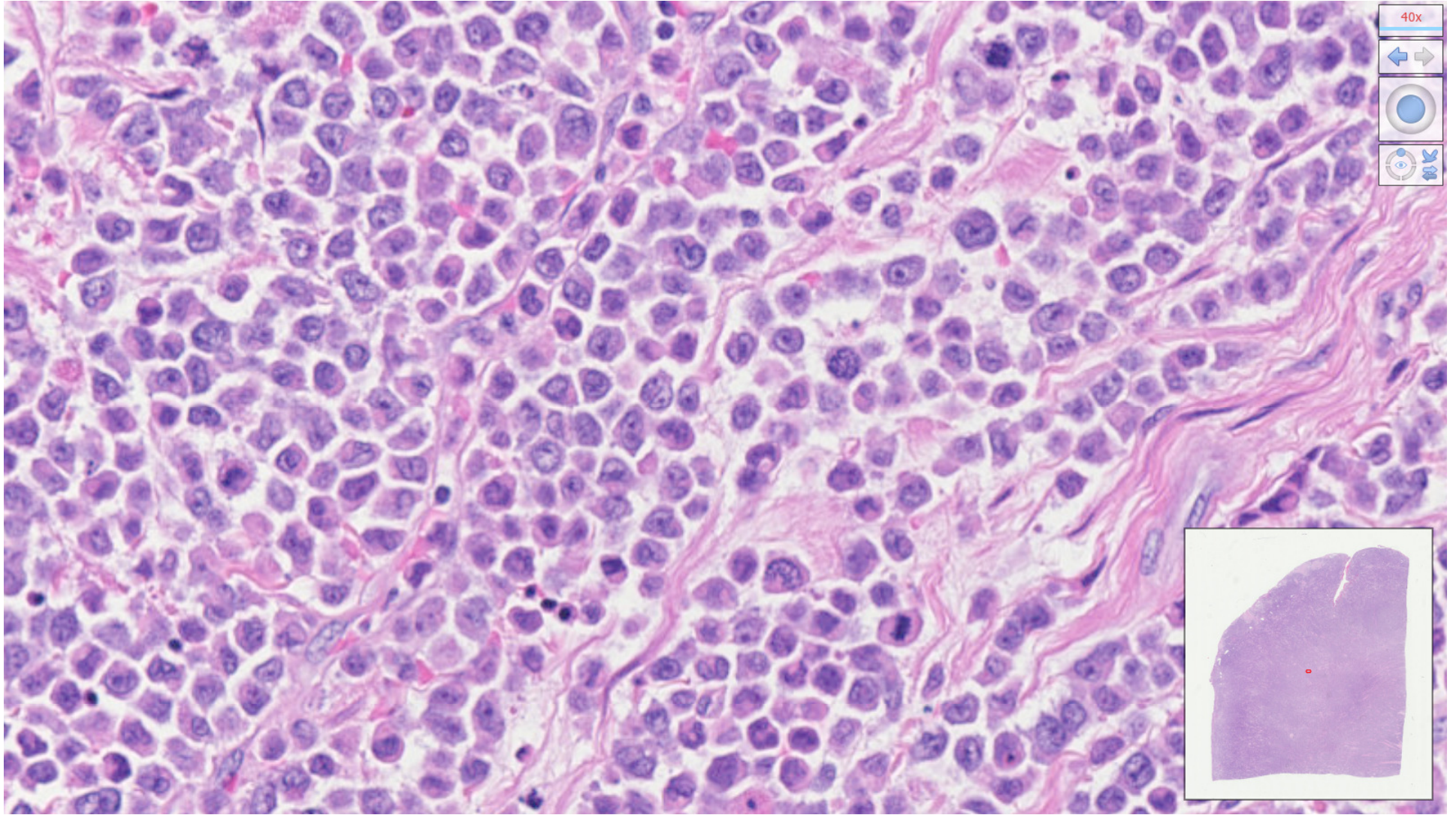
- Case-4

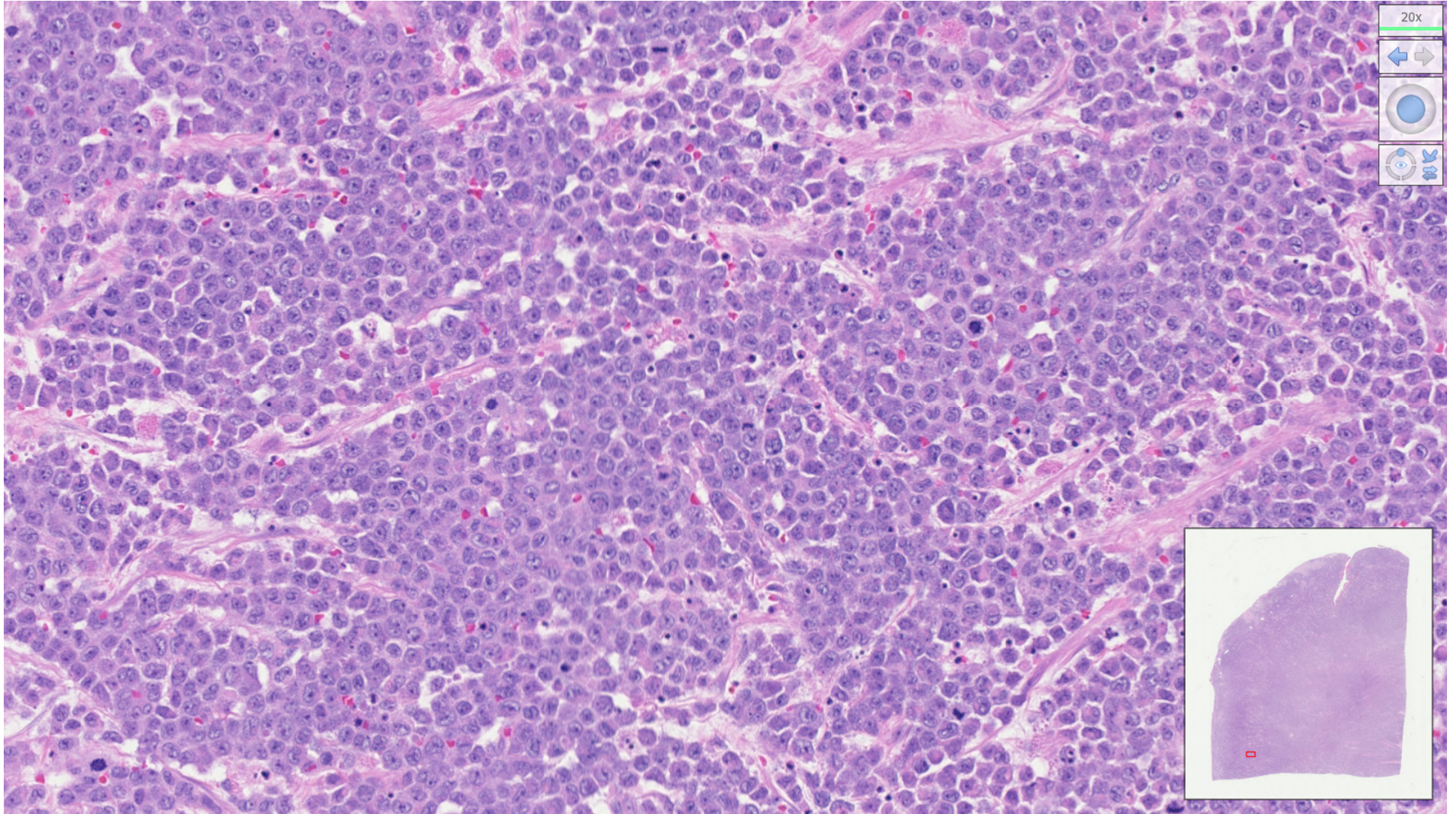
A 53-year-old female who presented with a 2-month history of a tender vaginal wall mass. She has been having menorrhagia that was thought to be due to uterine fibroids. Because of her menorrhagia, she underwent total hysterectomy and bilateral salpingectomy. During the procedure, an 8 x 5 cm solid mass on the right vaginal wall was noted and this was excised and submitted to pathology for examination.











20x

Navigation icons: left arrow, right arrow, zoom in, zoom out, and a circular refresh icon.

