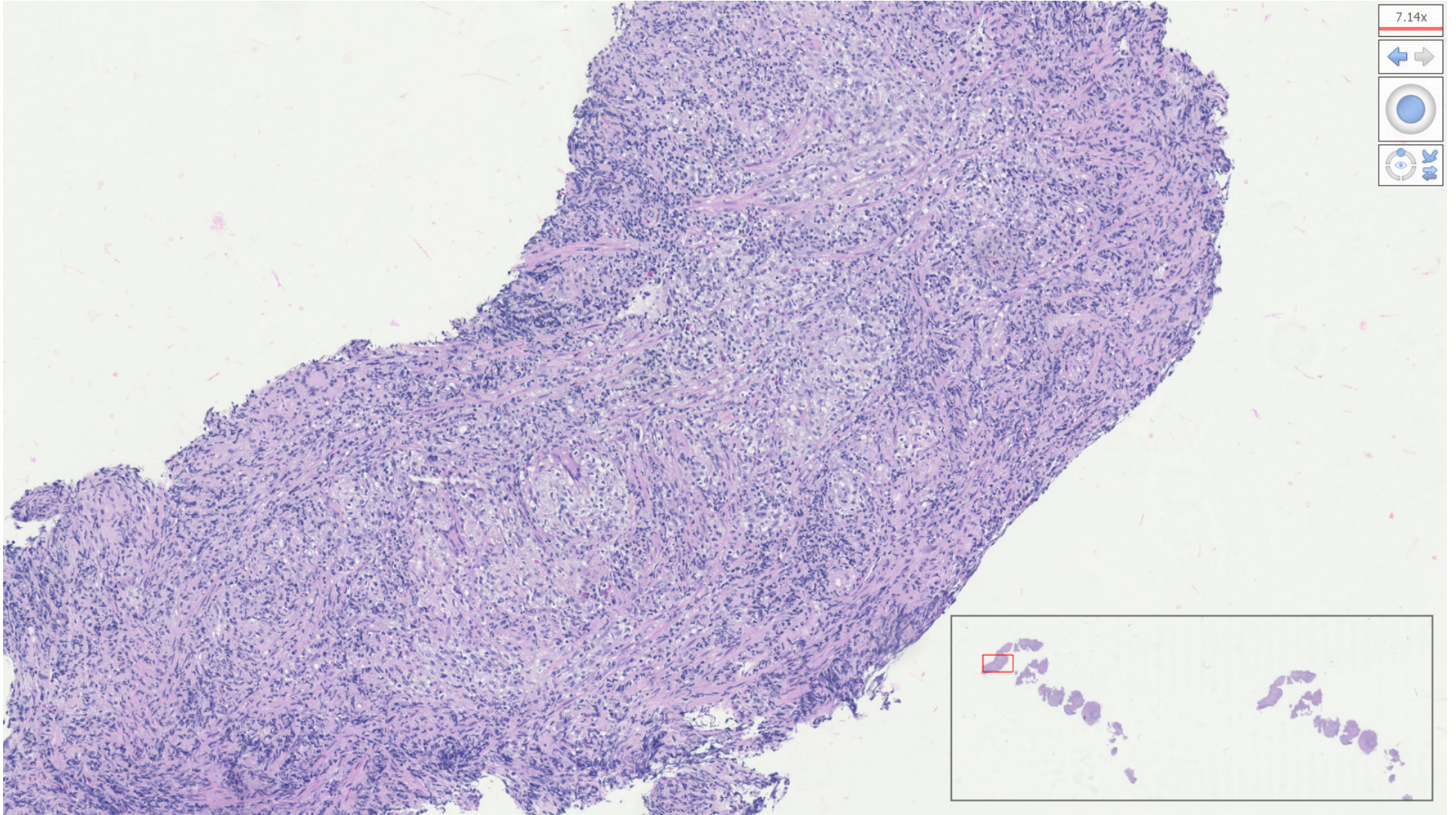


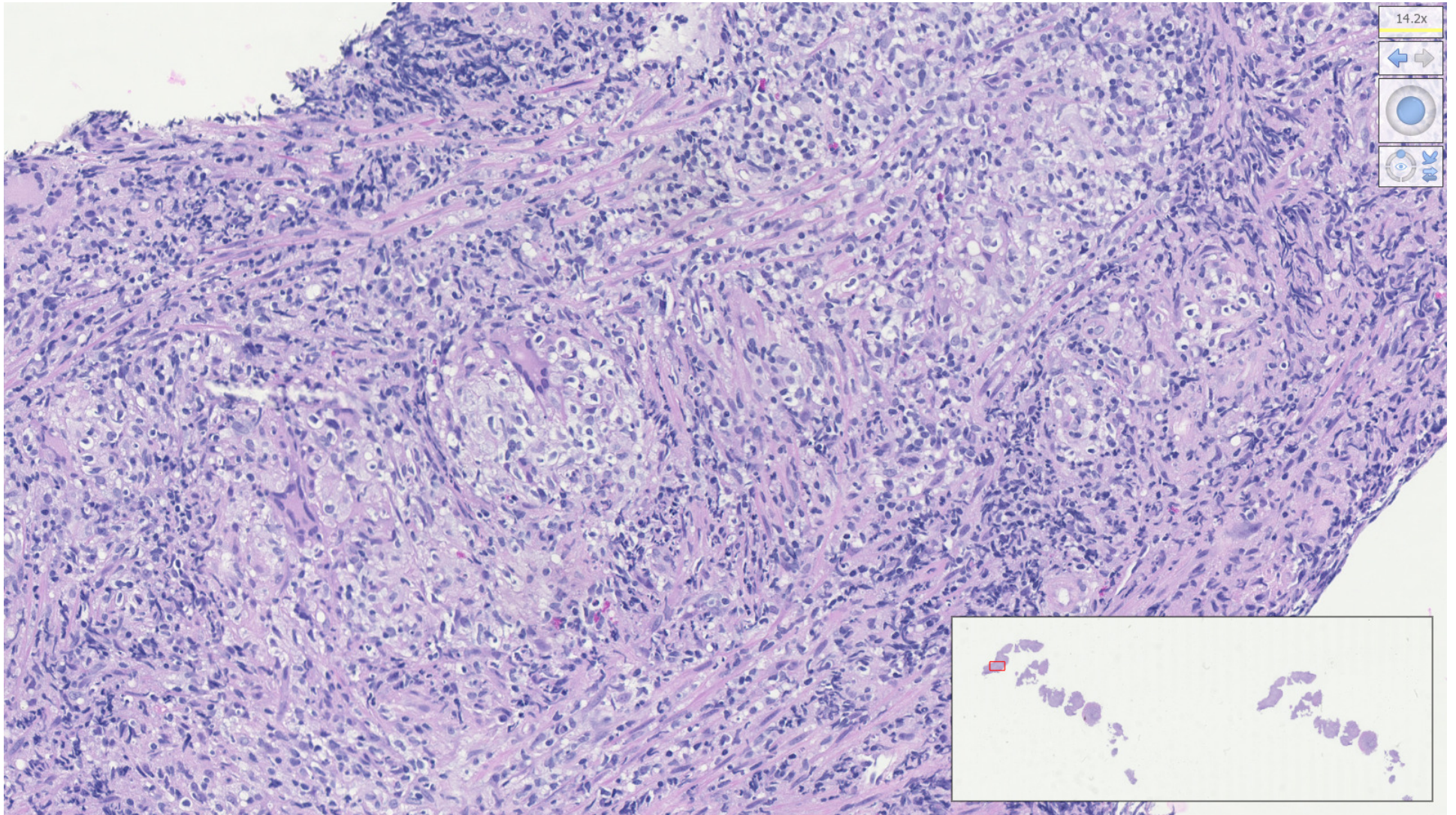
- Case-2

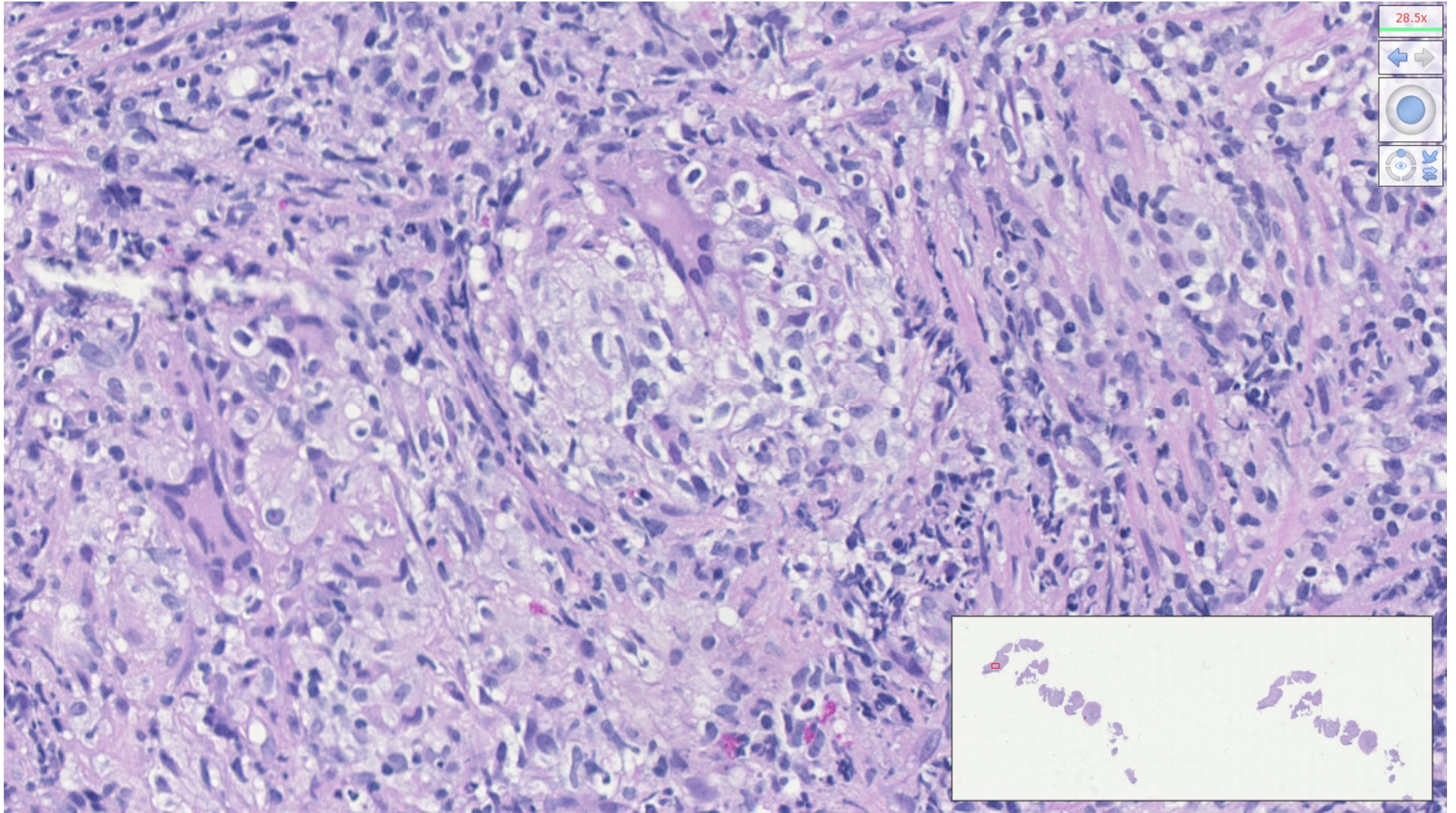
A 34-year-old male without significant medical history present to the ED for left lower quadrant pain. He reported two weeks constipation (not relieved by lactulose) and malaise. An abdominal CT scan revealed thickening of the rectal wall and enlarged pelvic lymph nodes. He was referred to gastroenterology where a digital rectal exam found a palpable rectal mass. A colonoscopy identified a 1.5 cm ulcerated submucosal mass in the rectum. The tissue sections are biopsies of this mass.

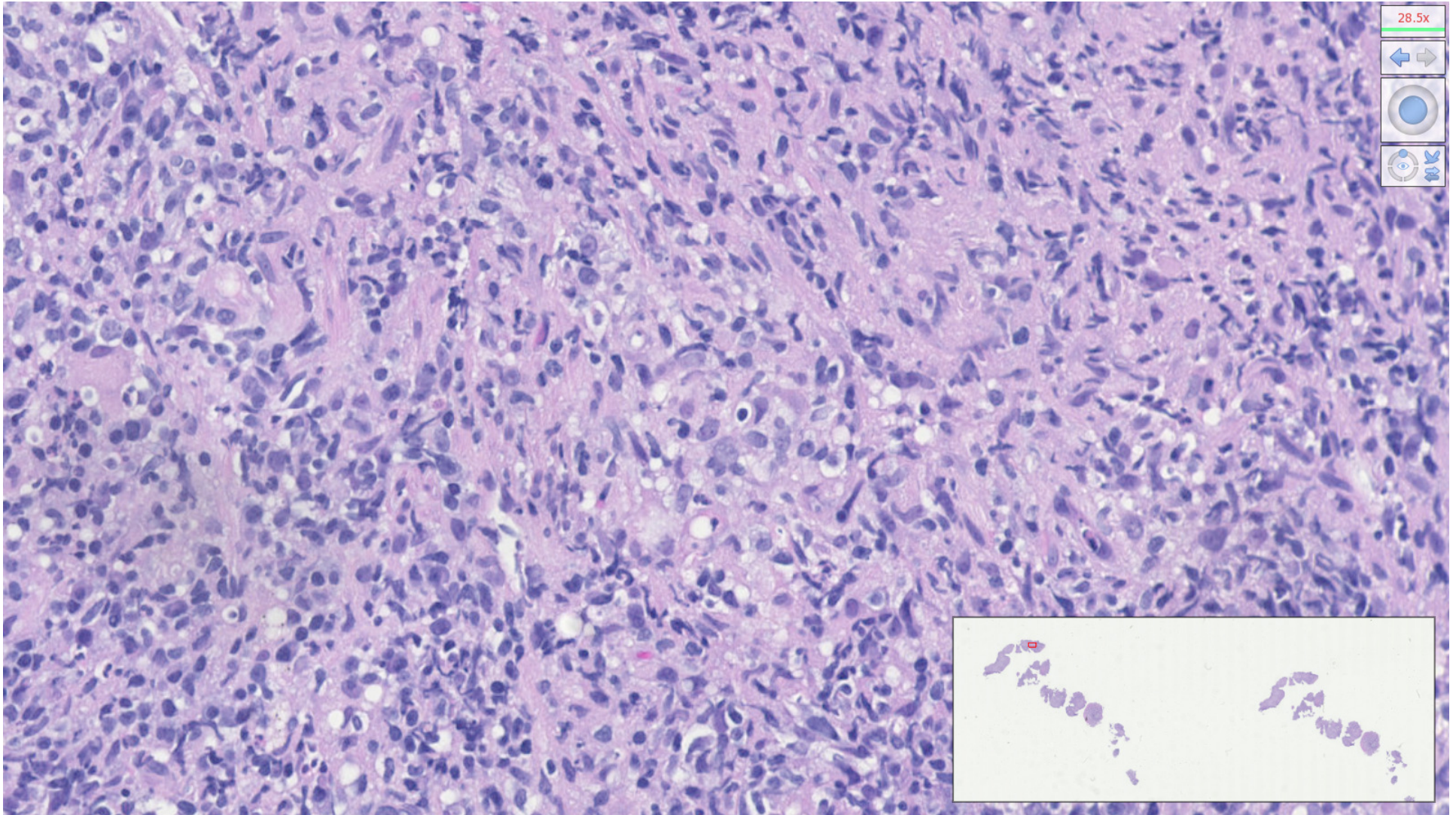


7.14x



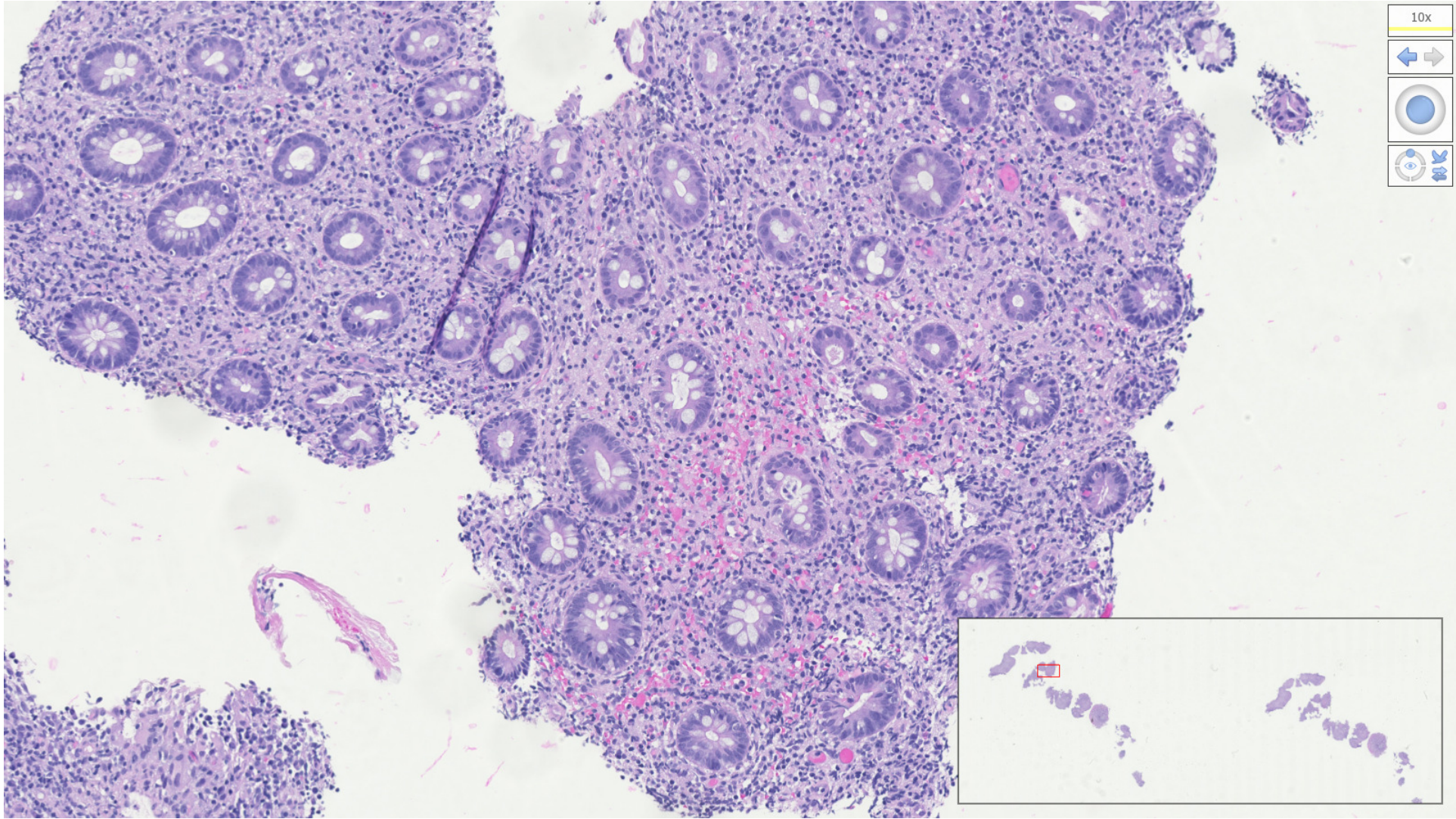






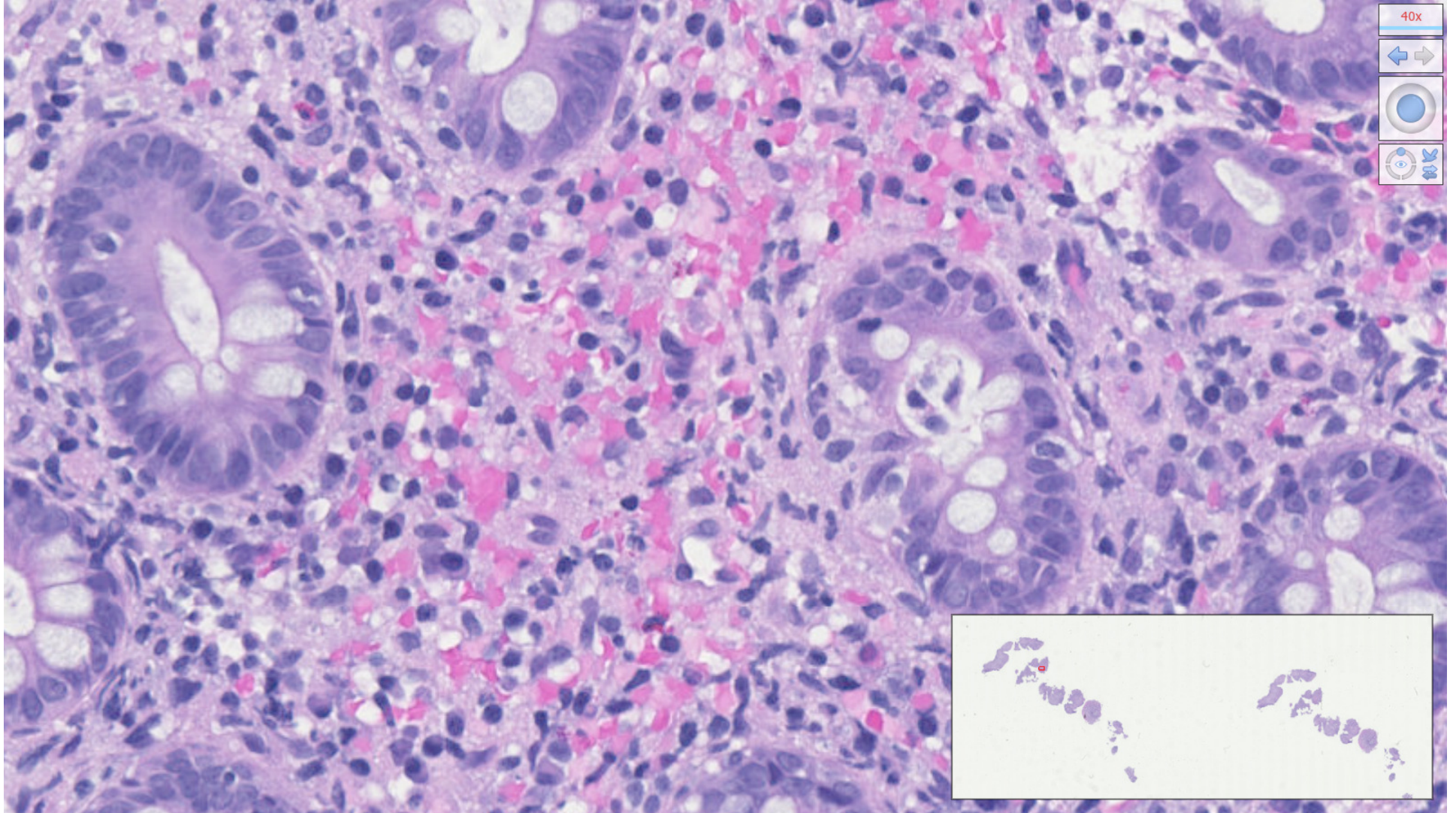
28.5x

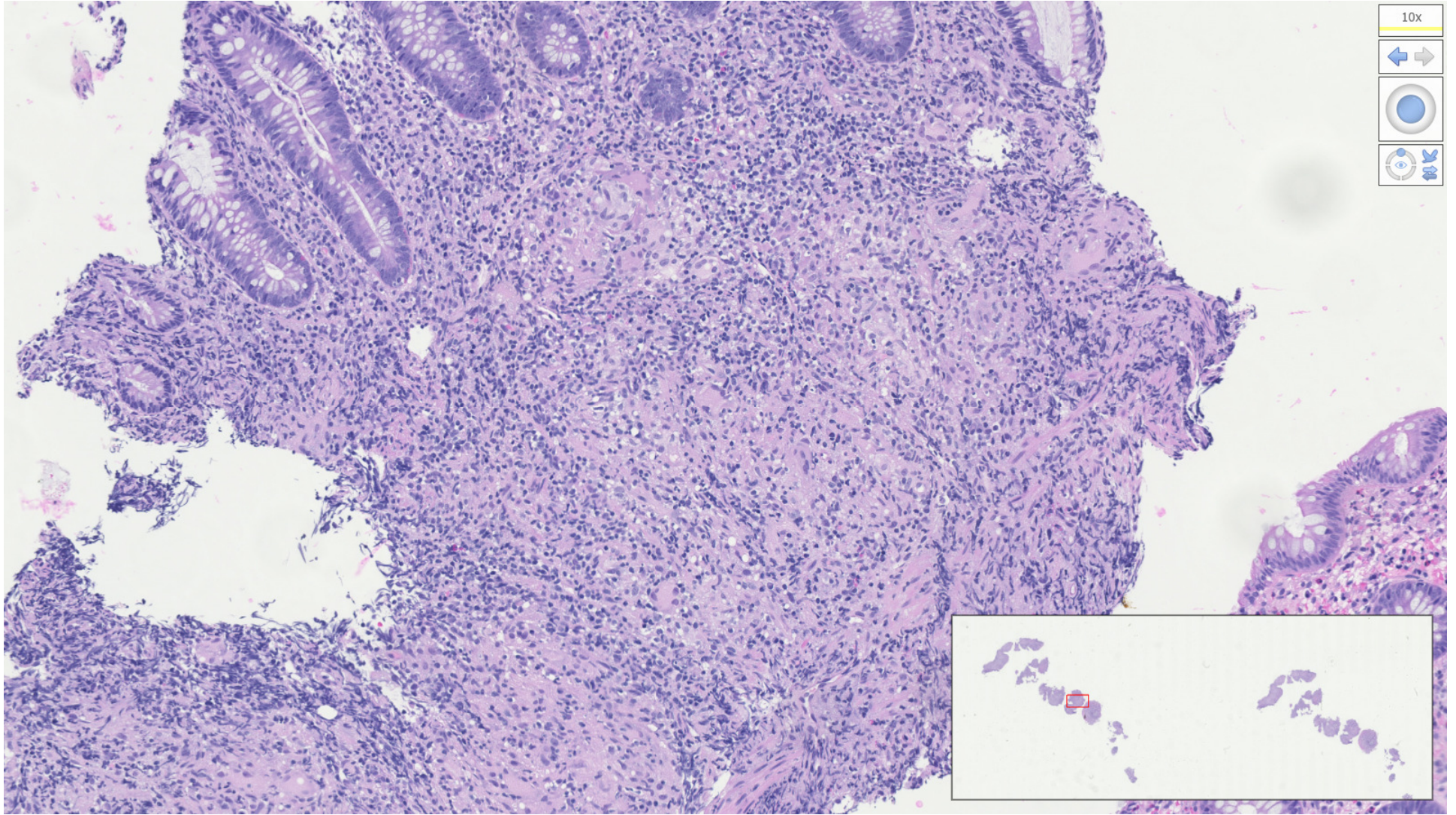
Navigation icons: left arrow, right arrow, zoom in, zoom out, and a magnifying glass icon.



10x

Navigation icons: left and right arrows, a circular zoom icon, and a double-headed arrow icon.





10x

Navigation icons: left arrow, right arrow, zoom in, zoom out, and a magnifying glass icon.



