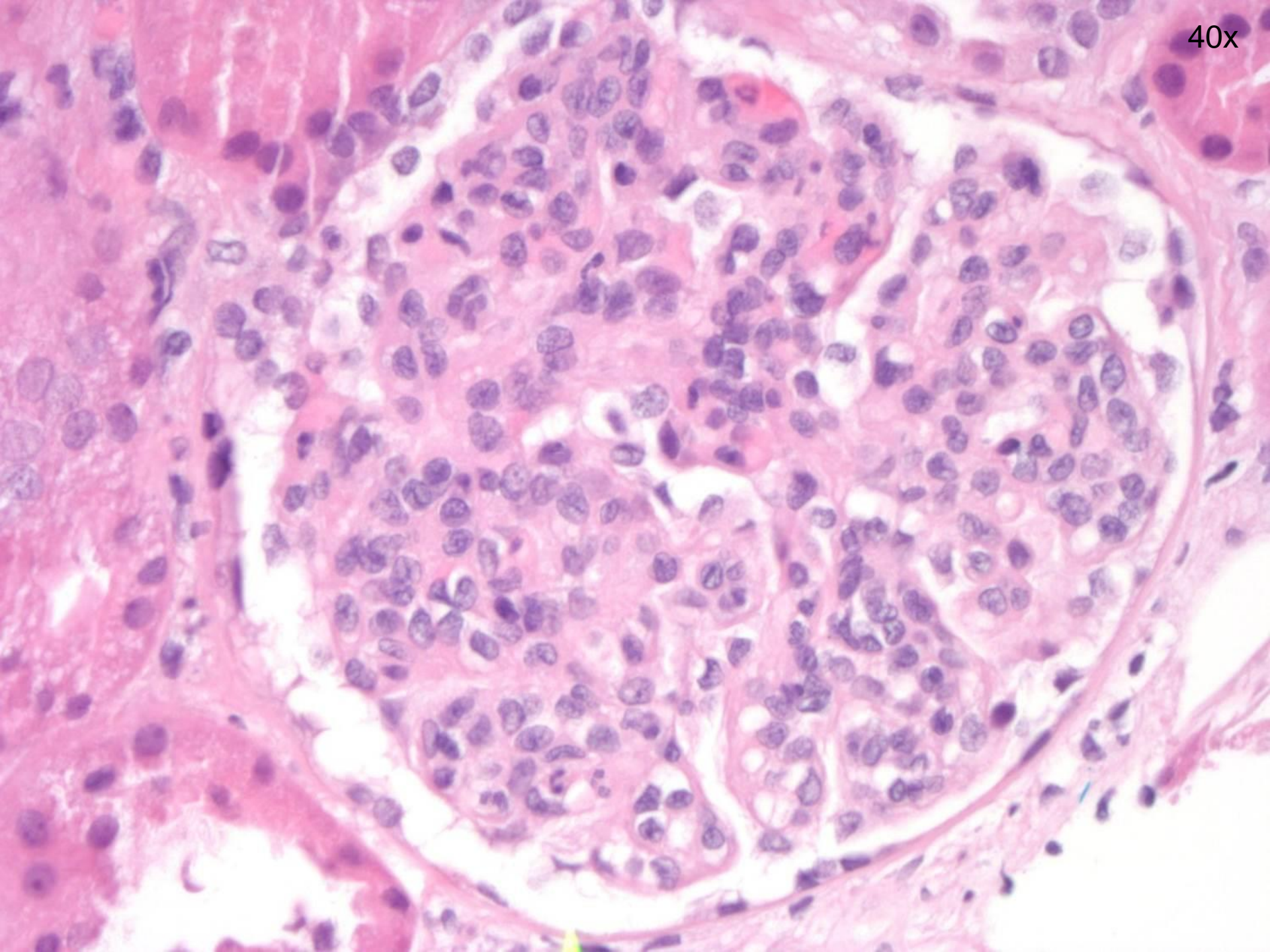


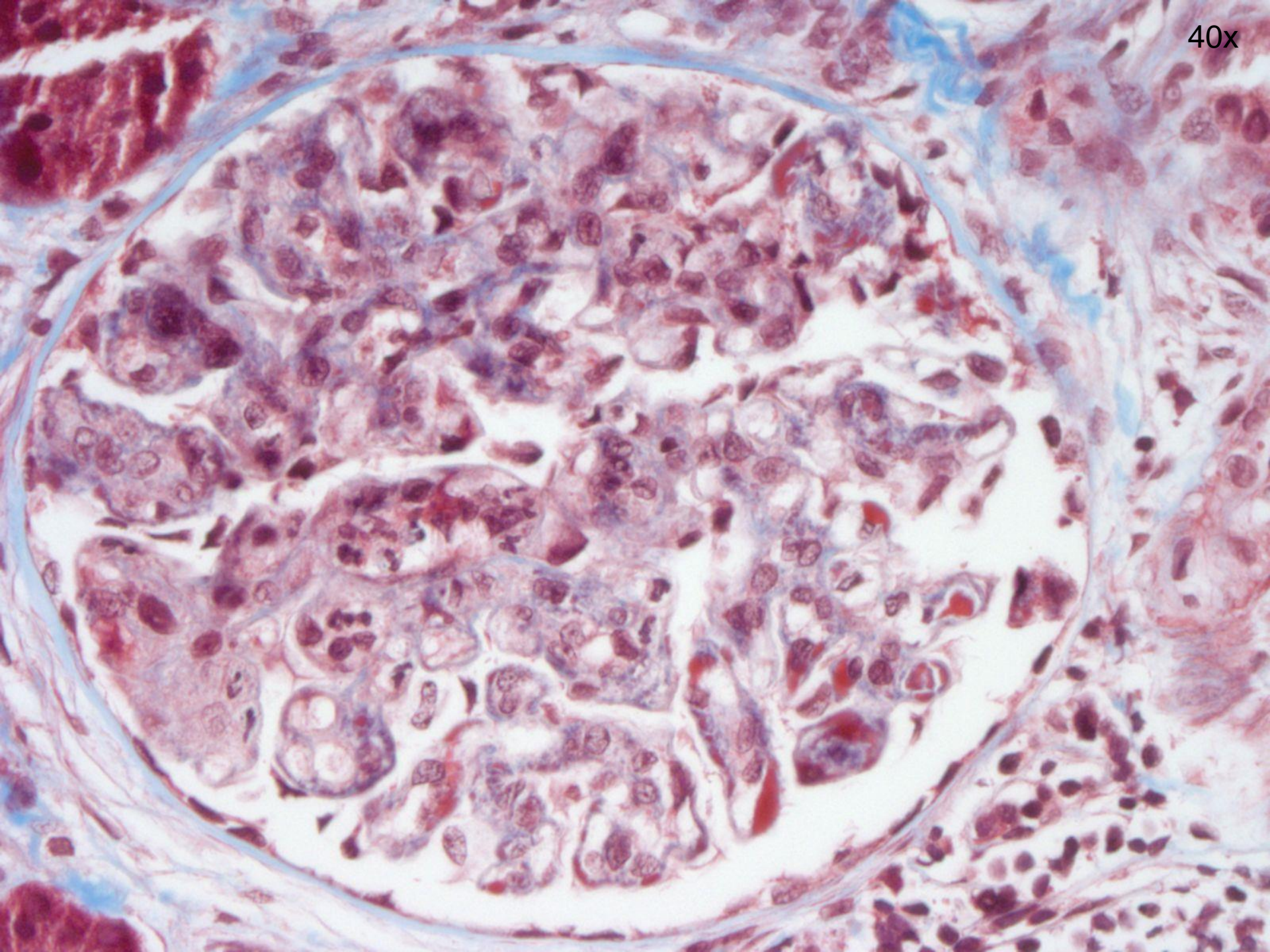
Case 4

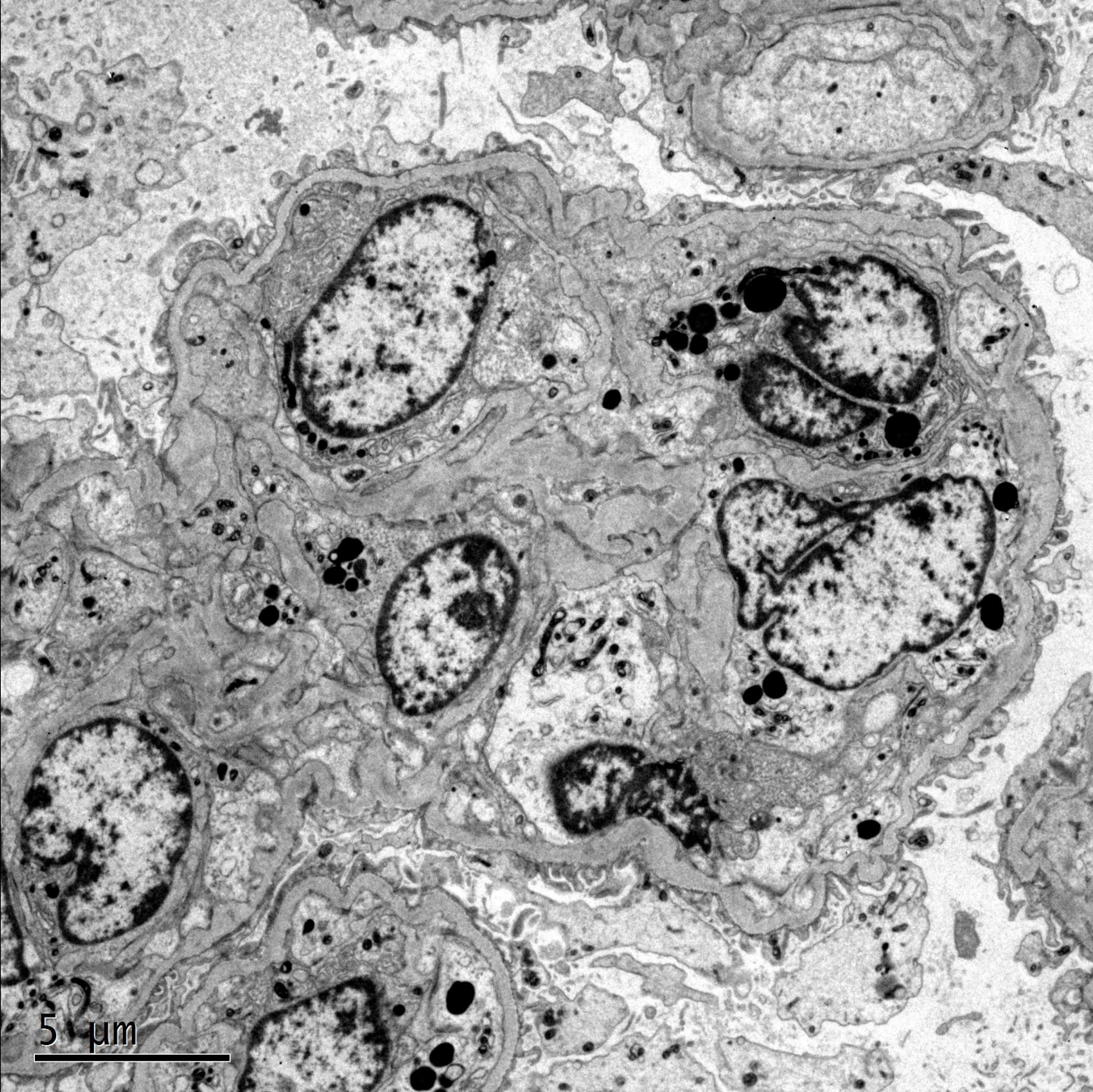
A 25 year old African American female presented with painful contractions. She was found to have severe pre-eclampsia with chorioamnionitis. She delivered a healthy baby boy via vaginal delivery and developed post-partum hemorrhage. She further developed acute kidney injury (creatinine 2.7, uric acid 12.8) with proteinuria. Renal biopsy was performed.

40x



40x

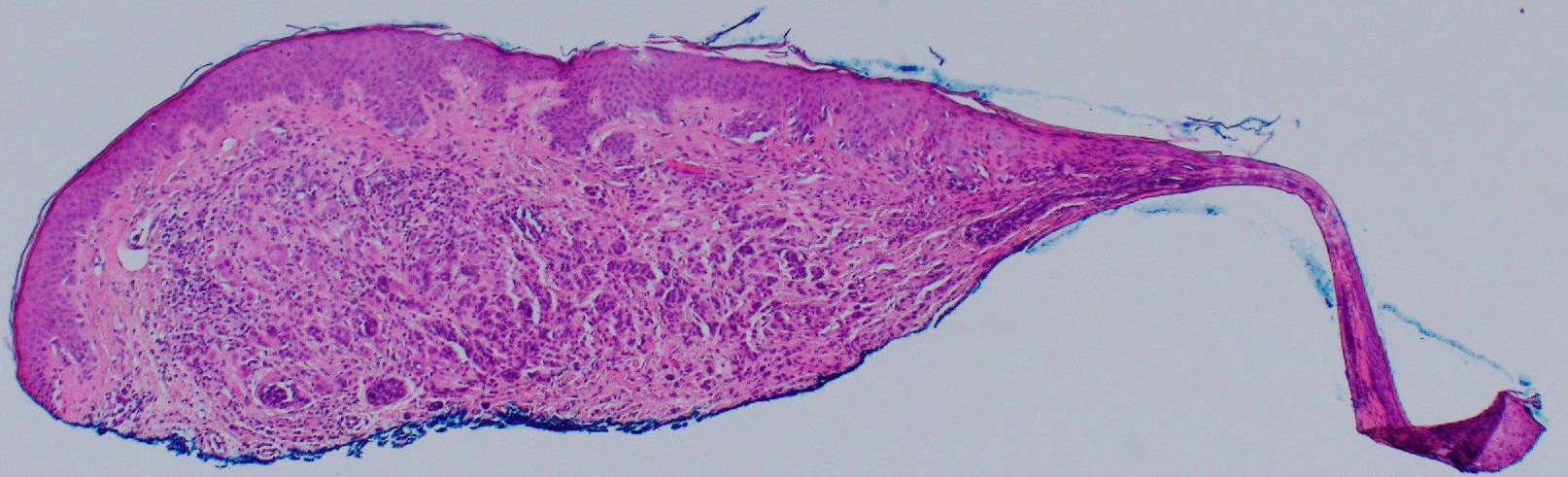




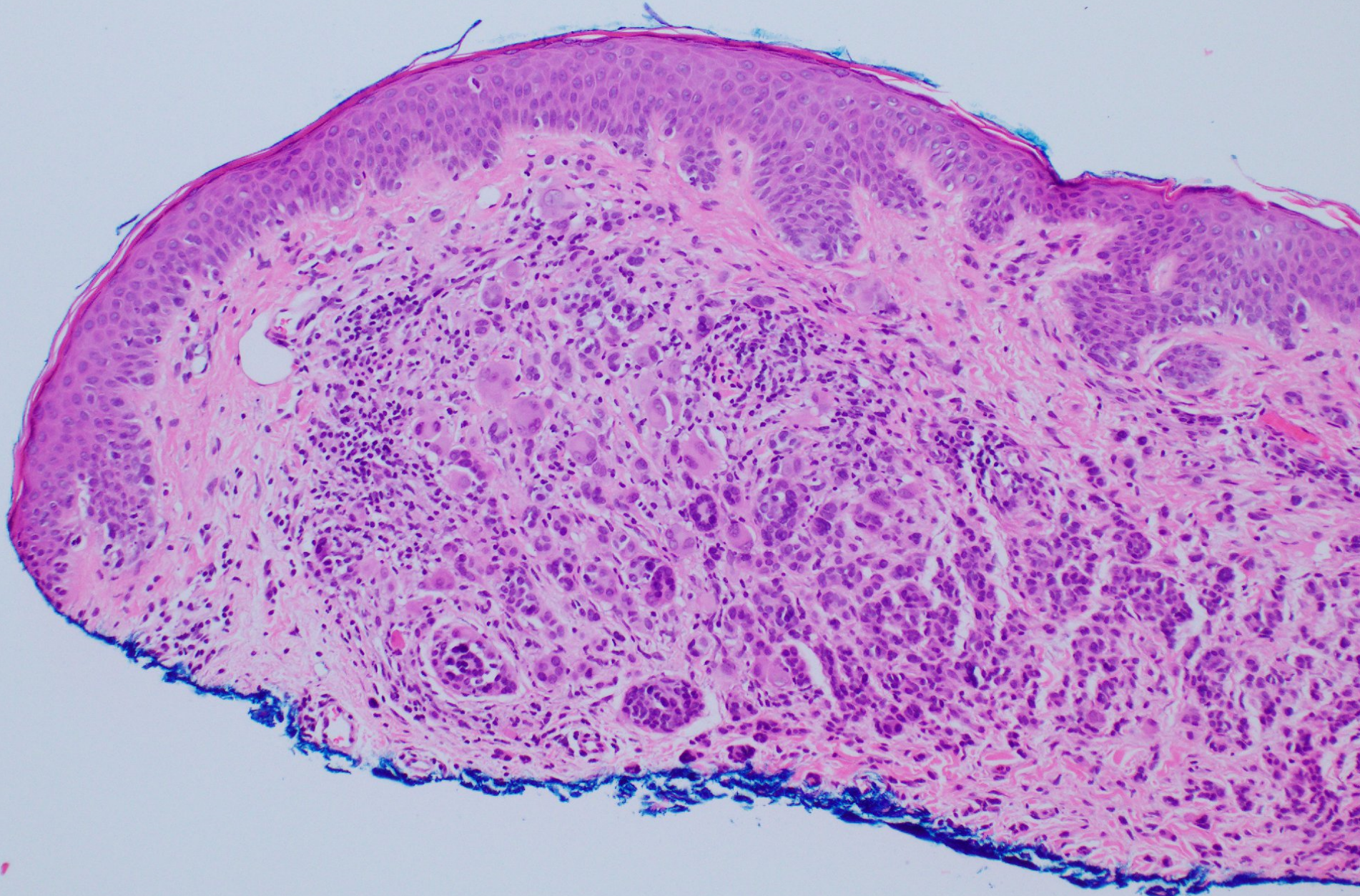
5 μm

Case 5

A 23 year old female with a history of metastatic melanoma and dysplastic nevi presents for follow up. A new scalp lesion is identified and biopsied.



10x



20x

