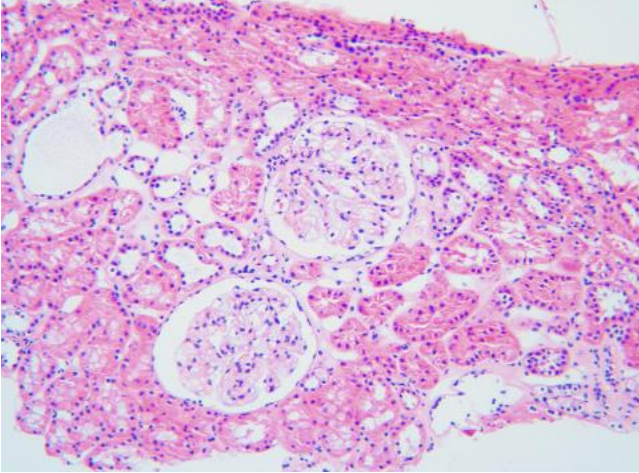
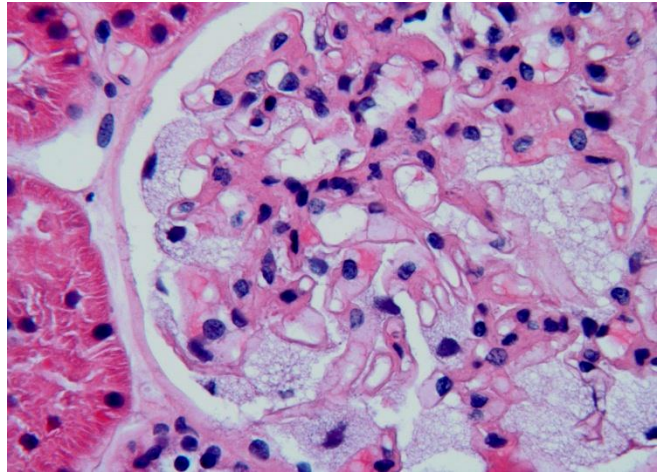


IRAP November 2015, Rush University Medical Center
Case # 5

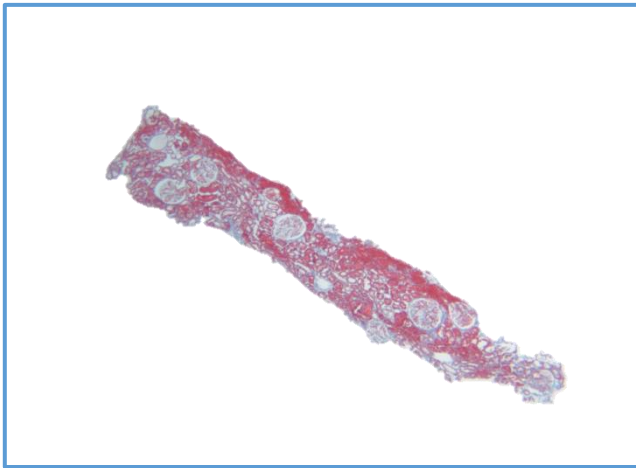
1) H&E stain



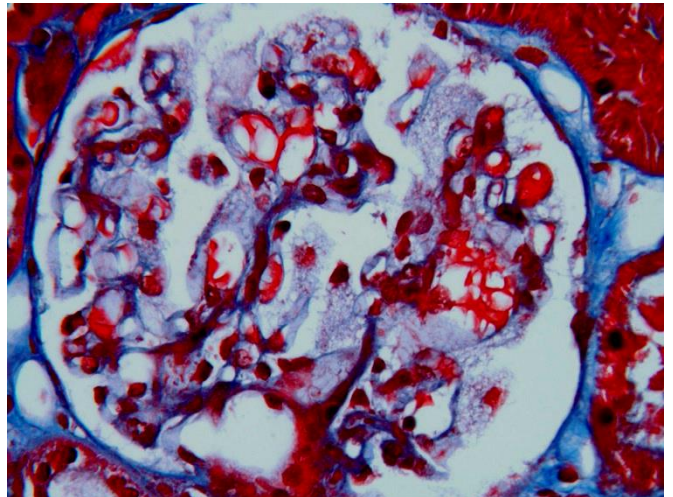
2) H&E stain



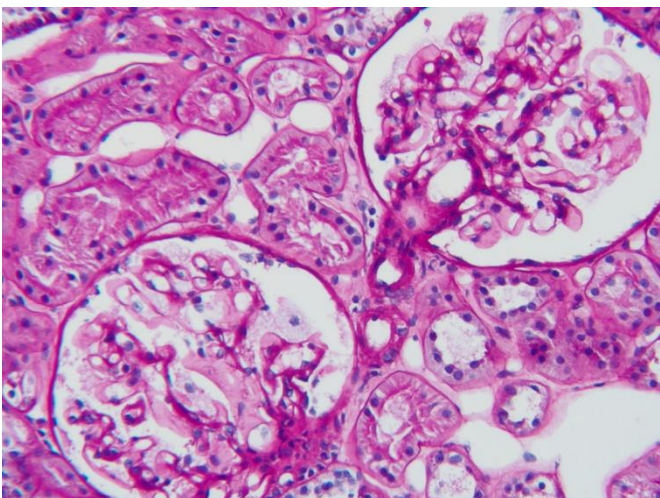
3) Trichrome stain



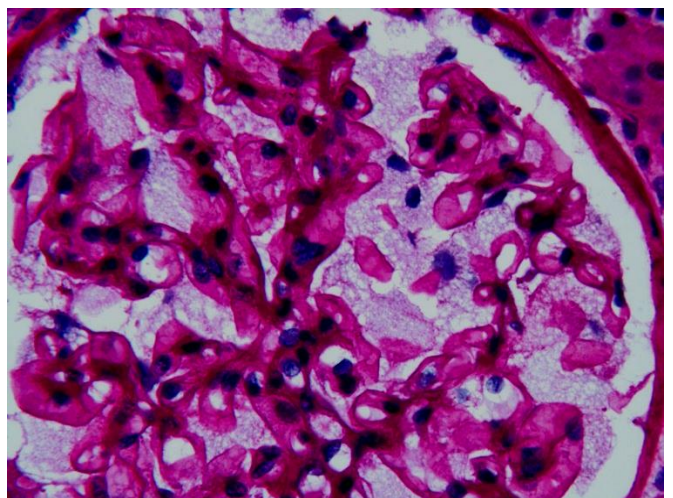
4) Trichrome stain




5) PAS stain



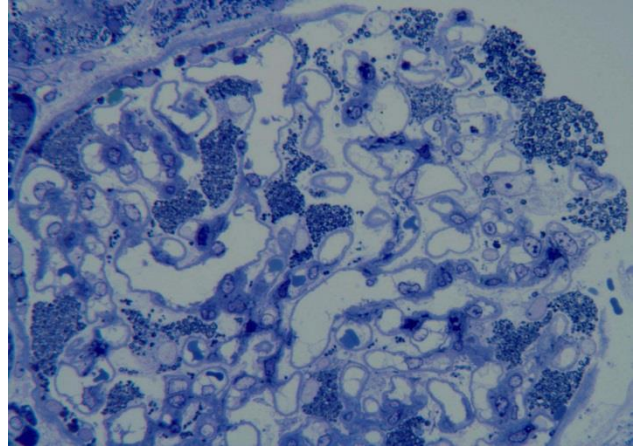
6) PAS stain



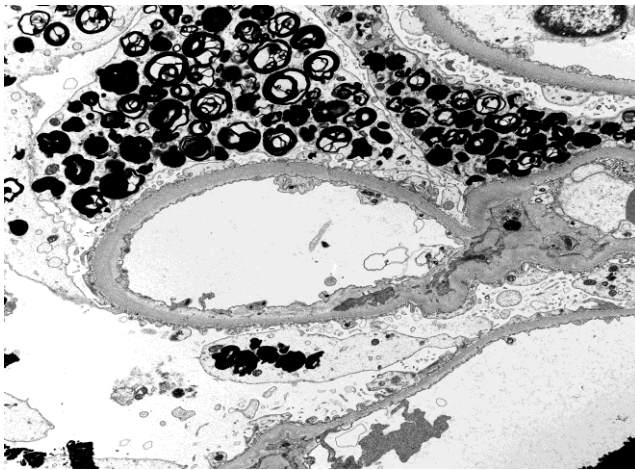
7) IgG immunofluorescence



8) Toluidine Blue Stain



9) Electron Microscopy



10) Electron Microscopy

